

OCULAR ENDOSCOPY: A REVIEW



This is an effective tool in eyes with poor media and for visualization and treatment of structures behind the iris.

BY JORGE G. ARROYO, MD, MPH

For retina specialists, standard pars plana vitrectomy (PPV) is the trusted approach to closed surgery for a variety of posterior segment conditions. In some cases—for example, significant trauma to the anterior segment—PPV with the OR microscope can be challenging or impossible. This is where the use of ocular endoscopy can be most advantageous.

The technology is straightforward and recognizable to anyone familiar with endoscopic surgery. Several systems are available in Europe, and two have US FDA approval (Endo Optiks E2 and E4, BVI Medical). A camera, a light, and, in some systems, a laser are incorporated into a single curved or straight housing. The instrument, in sizes from 18 to 23 gauge, is inserted through standard small-gauge vitrectomy incisions.

Over the past 25 years, I have had the opportunity to use ocular endoscopy for a range of retina applications. This dive into the literature reviews some of the best evidence for use of this technology.

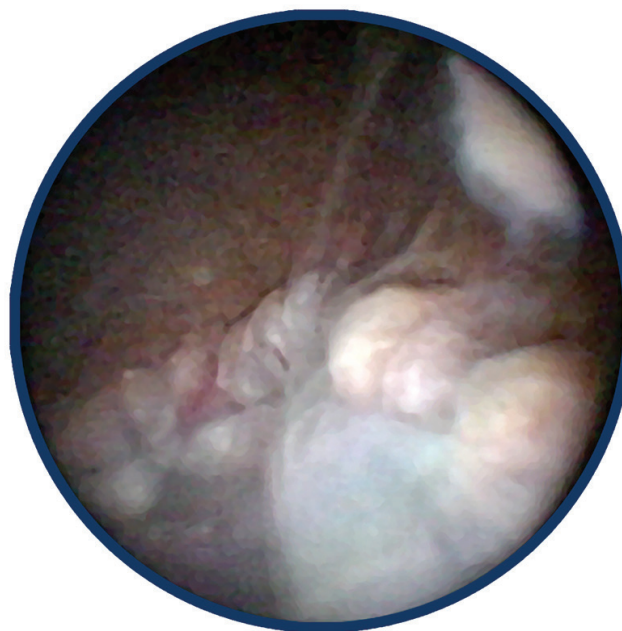
VISUALIZE THE POSTERIOR SEGMENT

Most patients who require posterior segment surgery can undergo standard PPV using an operating microscope, but when injury or disease prevents visualization of the posterior segment, ocular endoscopy may be a relatively simple and effective option.

In severe open-globe eye injuries, when significant trauma

AT A GLANCE

- ▶ When injury or disease prevents visualization of the posterior segment, ocular endoscopy may be an effective viewing option.
- ▶ A key advantage of endoscopy in these cases is that it offers a less invasive method of visualizing the posterior segment of the eye compared with a temporary keratoprosthesis.
- ▶ Endoscopy may reduce the chances of iatrogenic lenticular trauma and retinal breaks in pediatric vitrectomy.



Courtesy of BVI Endo Optiks.

Figure 1. Endoscopic view inside eye with focal abscess associated with endophthalmitis.

to the anterior segment prevents us from getting a clear view, we can bypass the anterior segment with the endoscope to achieve the necessary visualization. Temporary keratoprosthesis is another much more invasive and complicated option in such cases due to the difficulty of creating a watertight seal in a traumatized eye and the need for suturing of the corneal graft at the conclusion of the case. These patients also have increased risk of needing penetrating keratoplasty in the future.

Studies comparing endoscopic vitrectomy to temporary keratoprosthesis for severe ocular trauma found that surgical outcomes were similar, but patients were treated more quickly with endoscopic vitrectomy because this approach is less invasive and requires less preparation.¹ Patients treated using endoscopy were also less likely to develop retinal detachments or advanced proliferative vitreoretinopathy.² One study reviewed outcomes in endoscopic vitrectomy performed on 50 eyes (43 with open-globe injuries and 36 with retinal detachment) for which PPV was not possible and donor corneas were unavailable. Retinas were reattached in about 91% of cases, and about 81% of

Courtesy of BVI Endo Optiks.

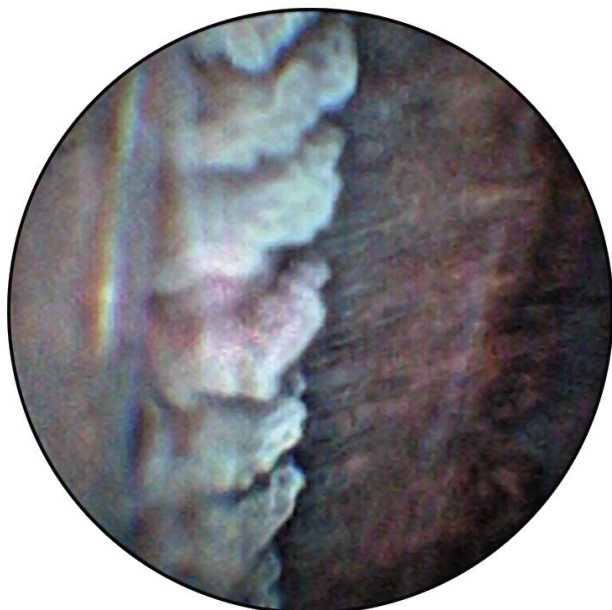

Figure 2. Endoscopic view of pars plana and ciliary processes.

patients had improved visual acuity postoperatively.²

Endoscopy offers the same advantages for visualization when the posterior segment is obscured due to disease (Figure 1). In posttraumatic endophthalmitis, PPV can reduce pathogens and inflammation and allow repair of retinal detachment,³ but patients with endophthalmitis often have anterior segment opacities. Endoscopy allows the surgeon to bypass those opacities to visualize the ciliary body (Figure 2) and other anterior structures. This approach has been shown to be safe for diagnosis and treatment.^{2,4}

SHORTEN DELAYS FOR TRAUMA SURGERY

In the aforementioned trauma cases, the deciding factor for using endoscopy was the inability to perform standard PPV with the OR microscope, usually due to anterior segment trauma. Limitations of the more invasive temporary keratoprosthesis procedure also influenced decisions. But another key advantage of endoscopy is evident: Patients can be treated sooner with endoscopy than with keratoprosthesis.¹ This is important because the longer surgery is delayed, the more time there is for inflammation to develop, ultimately increasing the odds of developing proliferative vitreoretinopathy, which will affect visual outcomes.

Intraocular foreign bodies (IOFBs; Figure 3) are present in 18% to 41% of open-globe injuries.⁵ When trauma involves an IOFB, delays can result in endophthalmitis in 10% of cases. Toxicity is a potential long-term complication; IOFBs that contain iron or copper can cause siderosis bulbi or chalcosis, respectively.^{5,6} The longer the IOFB remains in the eye, the greater the chance for it to become encapsulated and more difficult to remove.

Standard vitrectomy using the OR microscope is the first choice of treatment for IOFBs, but when poor visualization due to anterior segment trauma makes this approach impossible, endoscopic vitrectomy is a relatively simple and effective choice compared with temporary keratoprosthesis.^{1,7}

REDUCE DAMAGE IN NEOVASCULAR GLAUCOMA

When retinal conditions such as proliferative diabetic retinopathy and central retinal vein occlusion result in neovascular glaucoma, patients typically have an outflow procedure, such as trabeculectomy or tube-shunt surgery (although these approaches have a high failure rate in these patients), or a procedure that limits aqueous production such as cyclophotocoagulation. When cyclophotocoagulation is selected, endoscopic cyclophotocoagulation is the most common approach because its effect is more isolated than that of transscleral cyclophotocoagulation, resulting in less collateral tissue damage and less inflammation.^{8,9}

In a comparative study of standard care and endoscopic cyclophotocoagulation, the latter produced a significantly greater reduction in IOP (-28.5 mm Hg) compared with the former (-11.4 mm Hg).¹⁰ Visual acuity and complications were similar. In addition, endoscopic cyclophotocoagulation eliminated the need for medications in nearly three-quarters of patients, compared with 18.5% of patients who had standard care; other studies have shown similar results.^{11,12}

IMPROVE ACCESS IN PEDIATRIC CASES

The difficulty of working in the small vitreous cavity of a child increases the risk of iatrogenic lenticular trauma and retinal breaks.¹³ Endoscopic vitrectomy allows the surgeon to sustain visualization, potentially reducing the risk of trauma.⁸

A review of the literature shows that endoscopy has been used for a variety of pediatric indications.¹³⁻¹⁵ In persistent fetal vasculature, the perpendicular view offered by the endoscope can help surgeons identify safe nonvascular sites for amputation of the fibrovascular stalk.¹³ Applications of endoscopy for retinopathy of prematurity include accessing tractional retinal detachment located anteriorly near the standard vitrectomy trocar site, visualizing sclerotomy formation to prevent iatrogenic retinal breaks, and detecting anteriorly located vitreoretinal traction in advanced cases.¹³

OCULAR ENDOSCOPY PEARLS

Use of the endoscopic approach comes with a moderate learning curve, including training and wet-lab time. For practice, the endoscope can be used as a light source during routine procedures, which gives the surgeon time to get used to the medium and compare the views through the microscope and endoscope.

It is essential to hone the ability to identify landmarks seen through the endoscope so that the surgeon can maintain orientation. It gets easier over time to identify the

STANDARD VITRECTOMY USING THE OR MICROSCOPE IS THE FIRST CHOICE OF TREATMENT FOR IOFBS, BUT WHEN POOR VISUALIZATION DUE TO ANTERIOR SEGMENT TRAUMA MAKES THIS APPROACH IMPOSSIBLE, ENDOSCOPIC VITRECTOMY IS A RELATIVELY SIMPLE AND EFFECTIVE CHOICE COMPARED WITH TEMPORARY KERATOPROSTHESIS.

posterior pole and optic nerve and ciliary body structures.

It also takes time to accustom oneself to the endoscope's monovision view. Without stereoscopic depth perception, we can use other observations (magnification, shadows, and reflected light) to comprehend spatial relationships. In the future, stereoscopic endoscopy may be possible with 3D video displays.¹³

Other tips include putting the monitor near the surgeon's line of sight for the microscope to allow comfortable viewing. Also, understand that it will be necessary to use ultrasound to follow patients postoperatively because the anterior segment barriers to visualization will still exist.

The process of learning to use endoscopy is worth the effort for any retina specialist who treats trauma and complex cases. ■

1. Ayyildiz O, Hakan Durukan A. Comparison of endoscopic-assisted and temporary keratoprosthesis-assisted vitrectomy in combat ocular trauma: experience at a tertiary eye center in Turkey. *J Int Med Res*. 2018;46(7):2708-2716.
2. Sabti KA, Raizada S. Endoscope-assisted pars plana vitrectomy in severe ocular trauma. *Br J Ophthalmol*. 2012;96(10):1399-1403.
3. Shen L, Zheng B, Zhao Z, Chen Y. Endoscopic vitrectomy for severe posttraumatic endophthalmitis with visualization constraints [published online ahead of print. 2010 Mar 9]. *Ophthalmic Surg Lasers Imaging*. 2010;1-4.
4. De Smet MD, Carlborg EA. Managing severe endophthalmitis with the use of an endoscope. *Retina*. 2005;25(8):976-980.
5. Loporchio D, Mukkamala L, Gorukanti K, Zarbin M, Langer P, Bhagat N. Intraocular foreign bodies: A review. *Surv Ophthalmol*. 2016;61(5):582-596.
6. Zhang Y, Zhang M, Jiang C, Qiu HY. Intraocular foreign bodies in China: clinical characteristics, prognostic factors, and visual outcomes in 1,421 eyes. *Am J Ophthalmol*. 2011;152(1):66-73.e1.
7. Ben-nun J. Cornea sparing by endoscopically guided vitreoretinal surgery. *Ophthalmology*. 2001;108(8):1465-1470.
8. Marra KV, Yonekawa Y, Papakostas TD, Arroyo JG. Indications and techniques of endoscope assisted vitrectomy. *J Ophthalmic Vis Res*. 2013;8(3):282-290.
9. Goldenberg-Cohen N, Bahar I, Ostashiński M, Lusky M, Weinberger D, Gatot DD. Cyclocryotherapy versus transscleral diode laser cyclophotocoagulation for uncontrolled intraocular pressure. *Ophthalmic Surg Lasers Imaging*. 2005;36(4):272-279.
10. Marra KV, Wagley S, Omar A, et al. Case-matched comparison of vitrectomy, peripheral retinal endolaser, and endocyclophotocoagulation versus standard care in neovascular glaucoma. *Retina*. 2015;35(6):1072-1083.
11. Lima FE, Magacho L, Carvalho DM, Susanna R Jr, Avila MP. A prospective, comparative study between endoscopic cyclophotocoagulation and the Ahmed drainage implant in refractory glaucoma. *J Glaucoma*. 2004;13(3):233-237.
12. Uram M. Ophthalmic laser microendoscope ciliary process ablation in the management of neovascular glaucoma. *Ophthalmology*. 1992;99(12):1823-1828.
13. Yeo DCM, Nagiel A, Yang U, et al. Endoscopy for pediatric retinal disease. *Asia Pac J Ophthalmol (Phila)*. 2018;7:200-207.
14. Sasahara M, Kiryu J, Yoshimura N. Endoscope-assisted transscleral suture fixation to reduce the incidence of intraocular lens dislocation. *J Cataract Refract Surg*. 2005;31:1777-1780.
15. Ozgonul C, Besirli CG, Bohnsack BL. Combined vitrectomy and glaucoma drainage device implantation surgical approach for complex pediatric glaucomas. *J AAPOS*. 2017;21:121-126.

JORGE G. ARROYO, MD, MPH

- Retina Specialist, Beth Israel Deaconess Medical Center, Boston
- jarroyo@bidmc.harvard.edu
- Financial disclosure: None

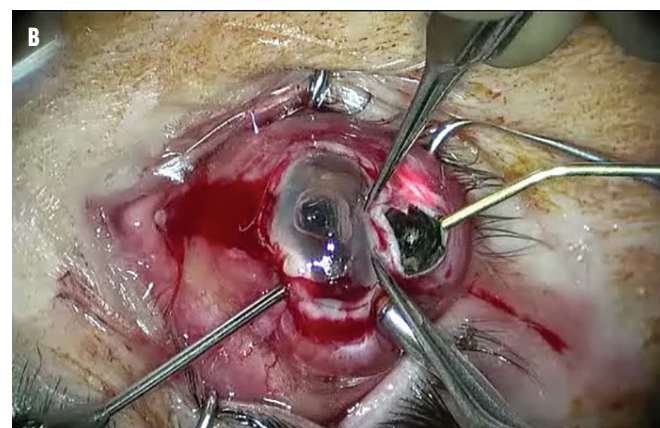
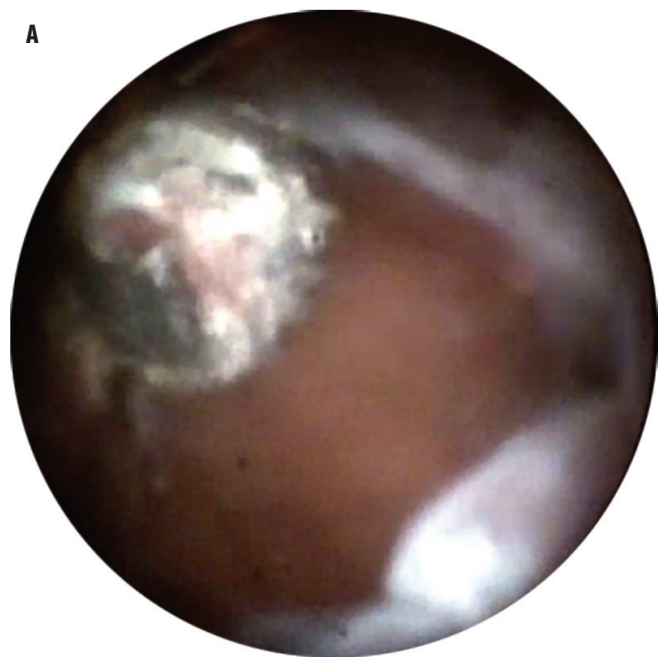


Figure 3. Endoscopic view of a large metallic IOFB (A), and microscopic view of the removal of the large metallic IOFB (B).

Courtesy of BV Edo Optiks